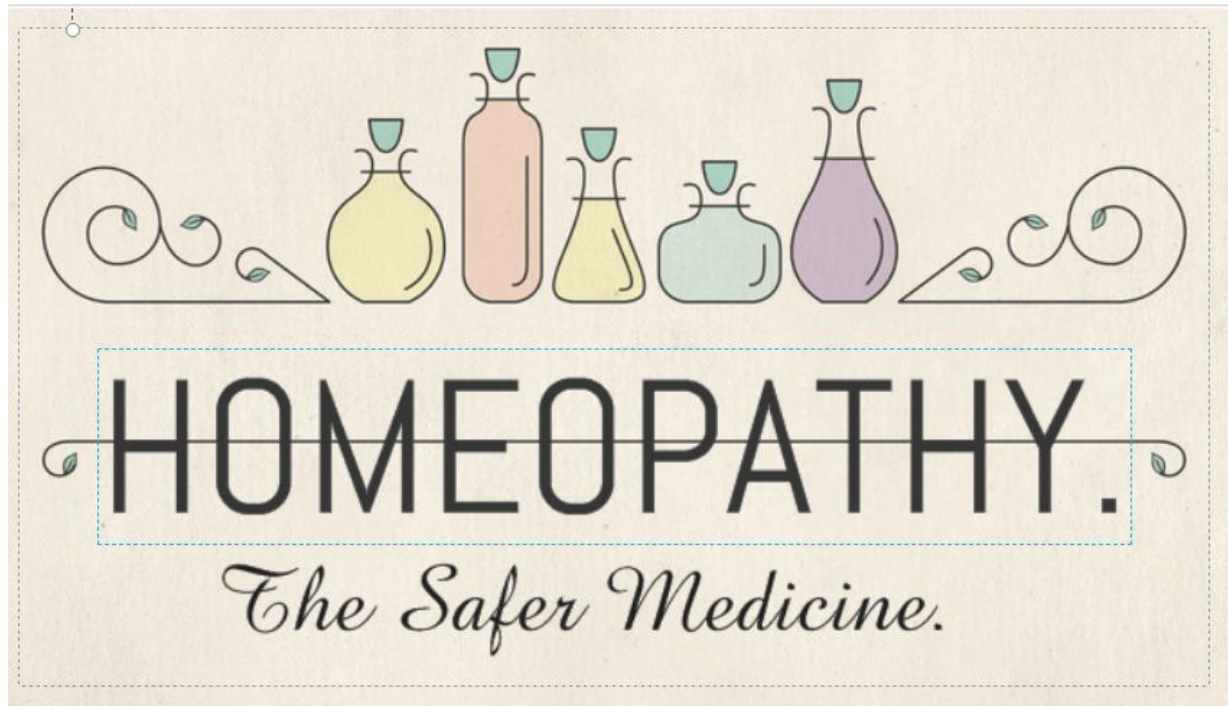



### **Introduction.**

Overuse, misuse, and abuse of drugs is one of the major problems mankind is facing nowadays. With many of the clinical studies and researchers exposing that many medicines prescribed and consumed by patients is causing side effects, and damage to their bodies; and many drugs even causing newer diseases to emerge, that the mankind is unfamiliar to; we are witnessing a tectonic shift in the medical industry to relatively harmless systems of medicines and treatments known as Alternative medicine such as Homeopathy and Ayurveda.

This explains the recent growth of these relatively side-effects free forms of medicine, widely known as Alternative medicine.

### **About Homeopathy.**

Homeopathy is a system of Alternative medicine developed in the Year 1796 by Dr. Samuel Hahnemann.

Contrary to modern medicine, which focuses on diseased part by giving material from of medicine to kill external particles like bacteria entering body, Homeopathy focuses on strengthening the internal dynamic vital force of the person, to overcome the derangement, which is often called as 'disease'.

The theory based on "Like Cure Like".His doctrine is Simila Similibus Curetur. For ex, red onion makes your eyes water. So it is used in Homeopathy for allergies;especially in allergic rhinitis where similar symptoms are present.

Homeopathy is derived from two Greek words- Homois meaning similar and Pathos meaning suffering. Homeopathy simply means treating disease with remedies prescribed in minute doses, which are capable of producing symptoms similar to disease, when taken by healthy people.

### **Simila Similibus Curetur.**

It is a natural law of healing.

Disease means dynamic vital forces deranged and Homeopathy consider the person as a whole, and based on totality of symptoms, SAME, SIMILAR, MINUTE DOSE, DYNAMIC MEDICINE, are used.

Contarary to this, for example, Cinchona can produce symptoms of Maleria in a healthy person. When Homeopathic medicine strengthen the vital force and immunity, no two similar force can stay together in body;Hence the weaker one will be eliminated from the body permanently, and the end result is the permanent cure, that is the **Simila Similibus Curetur**.

Hence Homeopathy advocates the usage of 'MINIMUM SIMILAR DYNAMIC FORCE' on the body, with no side effects.



**Dr. Nimmy Francis.**

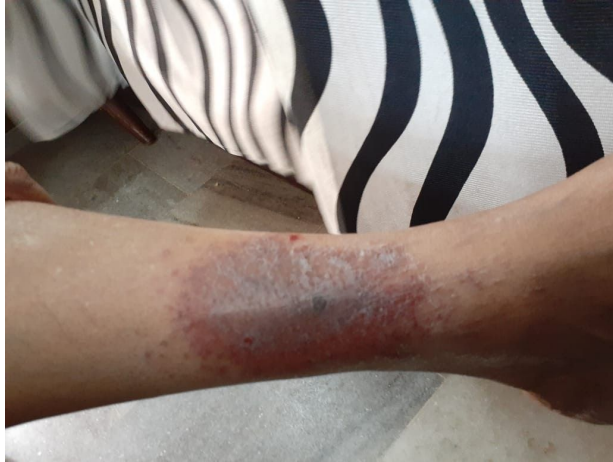Dr. Nimmy Francis graduated in the Year 2011,from Dr.MGR Medical University,which is ranked second in Asia.

Soon after graduating, she started her career by establishing her own Homeopathic clinic, at Cochin.

As of 2020,she has 9 Years of experience in treating and curing patients with various illnesses. Through continuous research, and experience gathered out of treating numerous patents,and carefully tracking down their course of improvement and recovery, Dr.Nimmy Francis has specialized and really positioned herself as a leading medical professional in the Country, in curing illness such as Allergic Rhinitis, Eczema, Psoriasis, Liver cirrhosis, Renal Stone, Chole

Lithiasis, Rheumatoid Arthritis, Piles, Fistula, Osteoarthritis, hormonal imbalance, hair loss, TSH, PCOS, Menopausal Syndrome, and chronic diseases like heart problem, kidney, and liver. Some of the important cases from her career so far are depicted below.

**Case No:1.**  
**Dermatitis.**



Mrs Lalitha 65 yrs female was suffering from macular eruption on leg with redness and severe itching was more on evening and night patient cant sleep due to itching and itching leading to oozing of blood and serum from the eruption known history of hypertension and hypothyroidism.

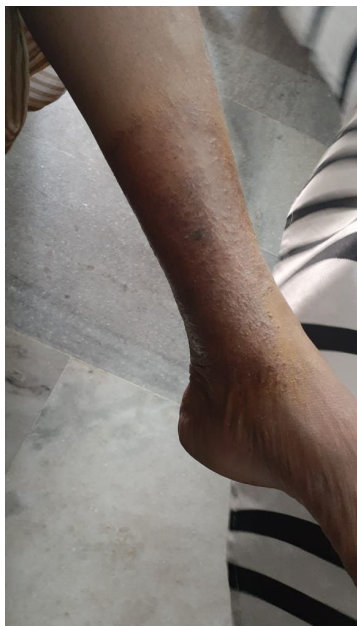Given

Rx

Rhus tox 30 (3\_3\_3)

Selenium 30 (3\_3\_3) echinacea q 10 drops 3 time per day in half ounce water for 2 weeks.

After 2 weeks patient came.



After two weeks there was no discharge and itching also reduced.

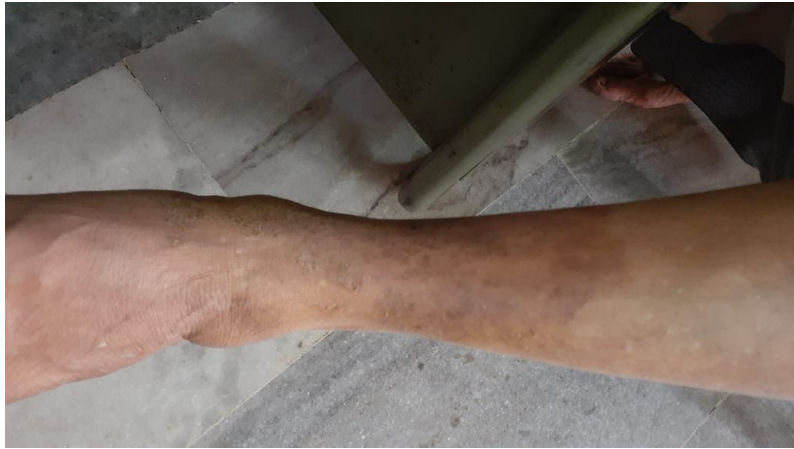Continue d medicine for 2 weeks more.

Rx

Rhustox 30 (3\_3\_3)

SL (4-0-4)

Echinacea q (\_10 \_10 \_10 ) in half ounce water.

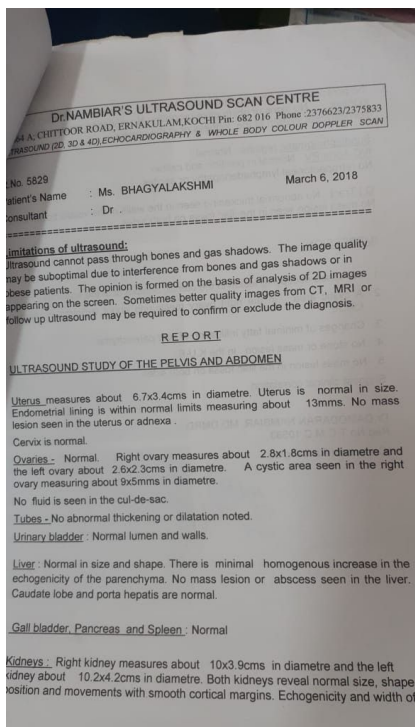


After taking medicine for 2 weeks the patient came to me. It was completely cured she was so happy.

## Case No:2

Bhagyalekshmi, 27 Year female was having delayed menses Dysmenorrhea, was present with back ache:Her scan report revealed that there is cystic area 9\*5 mm DM.

Reports.



the parenchyma within normal limits. No stone or mass lesion seen in the kidneys. No signs of obstructive uropathy. No distention of the pelvicalyceal system of the kidneys or in the ureters.

Subdiaphragmatic regions - Normal.

IVC, Aorta, PV - Normal in position and caliber. No retroperitoneal lymphadenopathy or ascites.

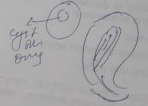
G.I Tract - No abnormal thickening seen in the walls of the visible small intestine. No mass lesion seen in the iliac fossa on both sides.

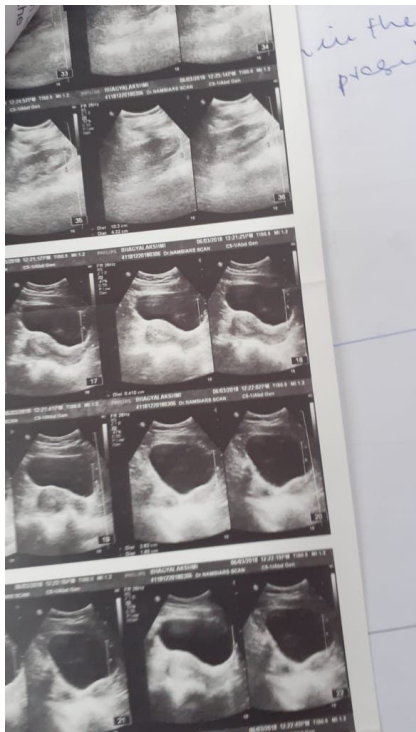**IMPRESSION:**

1. No space occupying lesion in the uterus, adnexa or in the abdomen.
2. A cystic area in the right ovary measuring about 9x5mm.
3. Changes of minimal fatty infiltration of liver parenchyma.
4. No stone or mass lesion in the K.U.B.
5. No mass lesion in the iliac fossa on both sides.

Suggest clinical correlation.

Dr. DAMODARAN NAMBIAR, MD, DMRD  
 Reg. No. T.C.M.C. 10583  
 (Consultant Radiologist)

*Handwritten notes:*  
 Cyst in the ovary  




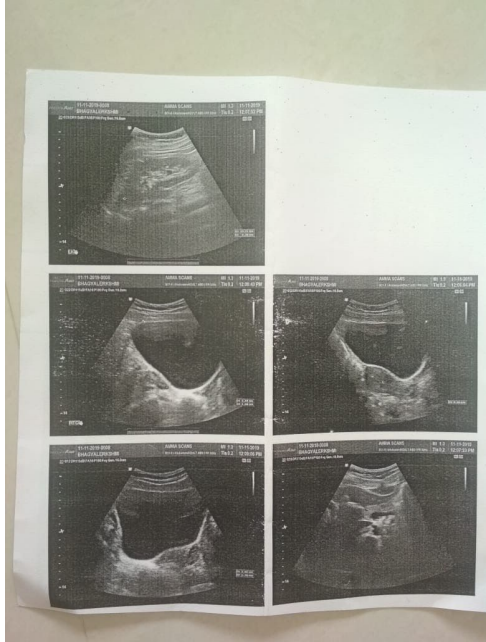
Rx

Took medicine. Pulse 200 tid.  
 Apis 200(3-3-3) For 3 Month.  
 After that, her mensus become normal.

Continued medicine for 6 Months. After that, scan report revealed no cystic mass.

Report After taking medicine.





### **Case No:3**

Micro Lithiasis.

Dia, 19 Year old female, was suffering from radiating pain from loin to groin on both side. No Nausea present. While urinating, she was having a burning sensation with colic pain in her lower abdomen. Done urine report and USG.

Urine report revealed urine infection and scan report revealed microlithmicrolithuaias.

Patient name Ms. DIYA J  
 Patient ID 20190822-164804-37EC / 30810  
 Referred by Dr. NIMMY FRANCIS

Age/Sex 20 Years / Fe  
 Visit No 1  
 Visit Date 22/08/2019 04

**Whole Abdomen Scan Report**  
**Real time B-mode Ultrasonography of Abdomen, KUB and Pelvis done**

**Abdomen**

**Liver**  
 Liver : Grade II fatty liver. Normal in size (spna 15.6cm), shape and outline with generalised homogenous increase in parenchymal echotexture. No focal lesions. Intra hepatic biliary radicles are not dilated. Portal vein is normal in course, calibre and outline with hepatopetal flow.

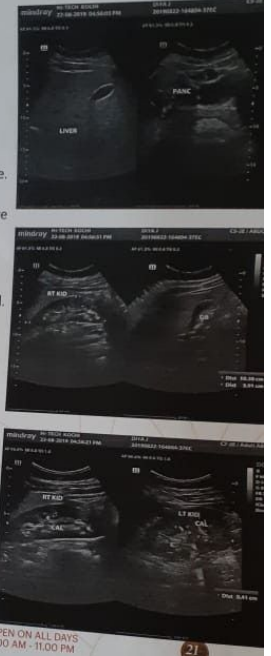**Gall Bladder**  
 Gall bladder is normal in distension, caliber and outline. No calculi. Wall thickness is normal. No pericholecystic fluid.

**Common Duct**  
 Common duct appeared normal. No calculi seen in the common duct.

**Pancreas**  
 Visualized extent of pancreas is normal in size & echo texture. No calcifications. No focal lesions. No duct dilatations.

**Spleen**  
 Normal in size & echo texture. No evidence of any focal lesions.

**Aorta**  
 Aorta appeared normal. No para aortic nodes seen.



International Stadium,  
 Metro Pillar - No. 54B  
 Kalarivattom, Kochi - 25  
 Ph: 0484-2333888 | www.hitechcochin.com  
 E-mail: info@hitechcochin.com

OPEN ON ALL DAYS  
 5:00 AM - 11:00 PM

Fully Automated Laboratory  
 Digital X-Ray ◊ Tread Mill Test  
 Pulmonary Function Test  
 Digital E.C.G. ◊ Echocardiogram  
 Colour Doppler Scan  
 Mammography ◊ NCV ◊ EEG

BEST LABORATORY TREATMENT  
 CAN GET NOW!

LAB DIRECTOR: Dr. N. Laxtha, MBBS, MD  
 Consultant Pathologist: Dr. Elizabeth George, MBBS, MD  
 CONSULTANT BIOCHEMIST: Dr. G. Jayachandran, MBBS, MD  
 Radiology: Dr. Parvathy S. Nair, MBBS, DMRD  
 Chief Technician: Mrs. Vaisa Varghese, CMA

PANDRATOM	PH: 2805444	7:00 AM -
POOJAKUDAL	PH: 2427773	8:00 AM -
KAKKANAD	PH: 2424777	7:00 AM -
KANGARAPADY	PH: 2481222	7:00 AM -
VENNALA	PH: 2803811	6:30 AM -
THANMANAM	PH: 2343465	6:30 AM -
EDAPPALLY	PH: 2544044	7:00 AM -
KALAMASSERY	PH: 2544441	7:00 AM -
CHEERHALDOR	PH: 2800047	7:00 AM -
VARAPUZHA	PH: 2334811	7:00 AM -
MOOTHALA	PH: 2433115	7:00 AM -
KATHIRKADAVU	PH: 2333811	6:30 AM -



DIYA J / 20190822-164804-37EC / 22/08/2019 / Visit No 1

**Endometrial Cavity**  
 Endometrial thickness measured 9.9 mm  
 Endometrial cavity appeared normal.  
 Endometrium is hyperechoic and uniform .  
 (Proliferative) .

**Right Ovary**  
 Right ovary measured 3.5 X 1.5 X 2.4 cms.  
 (Volume = 6.55 cc.)

**Left Ovary**  
 Left ovary measured 3.3 X 1.7 X 2.0 cms.  
 (Volume = 5.83 cc.)  
 Bilateral ovaries are mildly bulky with multiple  
 small peripheral follicles and central stromal  
 hypertrophy.

**Pouch of Douglas**  
 No Free fluid in the abdomen. Pouch of  
 Douglas is free.

**Impression**

- GRADE II FATTY LIVER
- BILATERAL RENAL MICROLITHS.
- POLYCYSTIC OVARIES.

DR. AMBILY CHANDRAN MD. ( AIIMS ) FRCR ( LONDON )  
 CONSULTANT RADIOLOGIST

**Disclaimer**  
 Note: Sonological evaluation has its limitations and the report should be correlated with use of other  
 modalities or clinical and other relevant patient data.

International Stadium,  
 Pillar - No. 54B  
 Mattom, Kochi - 25

Ph: 0484 - 2533888

www.hitchoochin.com  
 E-mail: info@hitchoochin.com

OPEN ON ALL DAYS  
 5.00 AM - 11.00 PM

21

Automated Laboratory  
 X-Ray • Tread Mill Test  
 Lung Function Test  
 E.C.G. • Echocardiogram  
 Doppler Scan  
 Mammography • NCV • EEG  
 LABORATORY TREATMENT  
 GET NOW!

LAB DIRECTOR : Dr. R. Leela, MBS, MD,  
 Former M.D., St. Mary's Medical College, Chennai

CONSULTANT PATHOLOGIST : Dr. Elizabeth George, MBS, MD

CONSULTANT BIOCHEMIST : Dr. G. Jayachandran, MBS, MD  
 Lab in Charge, PG Medical College, Coimbatore

RADIOLOGY : Dr. Parvathy S. Nair, MBS, DMRD,  
 Dr. Manu Jose, MBS, MD

CHIEF TECHNICIAN : Mrs. Vaisa Varghese, CMAI

PADAYATTOM PH: 2805444  
 PADANJAL PH: 2427773  
 KANJIRAM PH: 2426777  
 KANGARANADY PH: 2402222  
 PH: 2803333  
 VEMBALA PH: 2343444  
 THAKKANNAM PH: 2344444  
 EDAPPALLY PH: 2344444  
 KALANKOZZY PH: 2805000  
 CHERANALLOOR PH: 2308111  
 VANDIYAR PH: 2433333  
 MADUTNALLA PH: 2338111  
 KATTIKKADAMU PH: 2338111

Rx.

Cantharis 30 (3-3-3)

Apis 200 (3-3-3)

Hydrangea q 10 drops in half ounce water, 3-4 times water per day.

Took medicine continuously for 3 Weeks. Her urine infection gone and stone also passed out while urinating, and the patient was completely cured.

